

**Original article:**

**Study of comparison of efficacy of topical voriconazole (1%) v/s topical natamycin (5%) in the treatment of fungal corneal ulcer**

**Dr.Nikhil Mahajan , Dr.Subhash Sharma\*, Dr.Kavita Bhatnagar**

Department of ophthalmology, NIMS , Jaipur , India

Corresponding author \*

---

**Abstract:**

Among the causes of corneal blindness in developing countries, infectious keratitis tops the list. Corneal ulceration results in 1.5–2 million new cases of corneal blindness annually posing a major public health problem, according to the World Health Organization (WHO) reports.<sup>1</sup> Fungi are the most common etiological agents which account for 30–40% whereas bacteria account for 13–48% of all cases of suppurative keratitis varying by the geographical area. An intact corneal epithelium doesn't allow majority of the microorganisms to enter the eyeball.

This study was conducted at the Department of Ophthalmology, National Institute of Medical Sciences (NIMS), Jaipur, Rajasthan over a period of 15 months. Study was conducted on 60 patients who came in Ophthalmology OPD of Department of Ophthalmology, National Institute of Medical Sciences (NIMS) with the clinical presentation suggestive of fungal keratitis and microbiologically proven fungal infection.

Hence, it can be stated that Voriconazole is comparable to Natamycin in coverage of fungal spectrum but may be more useful in controlling the fungal corneal infection with deeper infiltration of the corneal layers and into the anterior chamber. Voriconazole may decrease the chances of complications of deeper fungal corneal infections such as perforation and endophthalmitis and helps in faster control of fungal keratitis.

---

**INTRODUCTION**

Cornea is a transparent tissue of ocular surface which is vital for a healthy eye. Corneal diseases contribute a lot in ocular morbidity. The most recent NPCB published survey indicates that most common reasons for blindness in India are cataract 62.6%, refractive errors 19.7%, glaucoma 5.8%, posterior segment diseases 4.7% corneal opacity 0.9% and others contribute upto 7.0%. The cornea when damaged by any disease, reaching upto Bowman's layer or deeper layers leaves an irreversible scar such as nebular, macular or leucomatous opacities. These opacities cause visual inefficiency.

Among the causes of corneal blindness in developing countries, infectious keratitis tops the list. Corneal ulceration results in 1.5–2 million new cases of corneal blindness annually posing a major public health problem, according to the World Health Organization (WHO) reports.<sup>1</sup> Fungi are the most common etiological agents which account for 30–40% whereas bacteria account for 13–48% of all cases of suppurative keratitis varying by the geographical area. An intact corneal epithelium doesn't allow majority of the microorganisms to enter the eyeball. Due to penetrating or perforating ocular trauma or due to surgery, microorganisms can penetrate through a breach in the epithelium. Corneal

ulcer is a major public health problem in the developing countries besides other infections or injuries to the cornea. It frequently causes prolonged morbidity and loss of vision. Treatment of corneal ulcers has at best remained unsatisfactory across the health systems of the developing countries. Steps need to be taken to prevent it and manage it to prevent damage of vision or complete loss.

### **Corneal Ulcer**

Definition: Corneal ulcer is defined as the discontinuation of normal epithelial surface of cornea associated with necrosis of surrounding corneal tissue.<sup>2</sup>

From the clinical point of view it may categorised as:

- 1) Based on location: superficial and deep<sup>3</sup>
- 2) Based on nature of etiology: infectious, immune related, traumatic and degenerative.

Superficial keratitis: when infection is limited to corneal epithelium and bowman's layer.<sup>3</sup> Deep keratitis: when infection passes beyond the bowman's layer and reaches to the stroma.<sup>3</sup>

Inflammation of cornea (keratitis) could be infectious or non infectious. Non infectious keratitis may become infectious by pathogenic or non-pathogenic microbes and possibly resulting in risk of more sight threatening complications.

Infectious keratitis could also be suppurative and non-suppurative. Bacteria and fungi are the main suppurative keratitis causing organisms. Non-suppurative keratitis could be viral, spirochaetal, parasitic, allergic.

The causative agents of infectious keratitis frequently isolated in India are:

- Bacteria: Gram positive cocci and gram

negative bacilli

- Fungi: Filamentous fungi
- Viral: Herpes simplex virus
- Parasite: Acanthamoeba species

Infectious keratitis is leading cause of monocular blindness worldwide<sup>4</sup>, in some settings upto 50% keratitis are due to fungal infection<sup>5</sup>. Treatment of fungal keratitis is difficult and final outcome in respect of visual acuity are not so good.

Historically, fungal keratitis has been endemic in warmer climate as in India, and relatively uncommon in temperate regions.

Fungal keratitis may be caused by ocular trauma with organic matter or may related to contact lens wear or refractive surgery. Fungal keratitis may progress to fungal endophthalmitis, if not treated successfully that is potentially devastating condition. More than 20% postcataract endophthalmitis cases and as much as 44% of central keratitis are fungal in origin in India as indicated in recent reports.

The common culprits for fungal corneal ulcer are aspergillus and fusarium (filamentous) fungi.<sup>6</sup> Aspergillus is the most common etiological agent of fungal keratitis from India.<sup>7,8</sup>

### **MATERIAL AND METHODS**

This study was conducted at the Department of Ophthalmology, National Institute of Medical Sciences (NIMS), Jaipur, Rajasthan over a period of 15 months. Study was conducted on 60 patients who came in Ophthalmology OPD of Department of Ophthalmology, National Institute of Medical Sciences (NIMS) with the clinical presentation suggestive of fungal keratitis and microbiologically proven fungal infection.

Each patient signed an informed consent.

After evaluating following criteria, 60 patients were divided into two groups of 30 each:

Group V: Voriconazole group

Group N : Natamycin group

**INCLUSION CRITERIA:**

- Presence of corneal ulcer at the time of presentation (corneal epithelial defect with stromal infiltration & necrosis)
- Evidence of fungus filaments in the corneal ulcer on the smear (KOH wet mount, Culture on Sabouroud' s dextrose Agar, Gram's staining)
- Appropriate consent

**EXCLUSION CRITERIA**

- Corneal ulcer less than 0.5 mm at the time of presentation
- Presence of herpetic keratitis by the history and slit-lamp examination after fluorescent staining
- Bilateral ulcer
- Previous history of penetrating keratoplasty
- Pregnancy
- Known allergic to study drug
- No perception of light in affected eye
- Patient not willing to participate in study
- Corneal ulcer in immunocompromised and diabetic patients

All patients were made to undergo full clinical, ophthalmic and systemic evaluation.

**History** - Ocular, medical and family history of each patient is taken.

**Clinical Evaluation**

Clinical diagnosis including detailed history taking as well as thorough ocular and systemic examination was done in every subject and recorded.

**HISTORY:** The patients were questioned for:

Symptoms

- Pain, redness, watering, photophobia, blurring of vision, foreign body sensation.
- Time since onset of symptoms
- Events preceding the onset of symptoms
- History of trauma
- History of ocular surgery
- History of drug use - oral and topical
- History of contact lens use
- History of similar episode in the past
- Significant systemic history including history of hospitalization.

**OCULAR EXAMINATION:**

Full ophthalmological examination includes visual acuity, diffuse light examination and slit lamp examination.

Diffuse light examination includes corneal surface, shine, location of ulcer, presence or absence of discharge, hypopyon and lid edema.

Slit lamp examination includes measurement of ulcer size by slit beam in two maximum dimension, depth (involvement of stroma), anterior chamber reaction and hypopyon, presence of the corneal vascularization and examination of stained corneal ulcer with sodium fluorescent under cobalt blue filter.

### **DIAGNOSIS:**

Clinical diagnosis of fungal corneal ulcer is done on the basis of clinical features as the onset is usually insidious, often following corneal injury. The ulcer has a raised, wet, soft, creamy to grayish white infiltrate with unlevelled hypopyon. Feathery or hyphened margins and satellite lesions may also be seen.

The symptoms like pain, photophobia and redness are equal or less as compared to those seen in bacterial keratitis but lid edema is minimal.

Confirmed diagnosis was based on the detection of the fungus in the laboratory by the KOH wet mount and culture of the sample (corneal scrape).

### **CORNEAL SCRAPING:**

Scraping is collected after anaesthetising the cornea with 0.5% proparcaine drops and waiting for 2-3 minutes. With the help of sterile Bard-Parker blade No.15, scraping is done by applying multiple, moderately firm, unidirectional strokes, under slit lamp illumination. Material is collected both from the base as well as from the edge of the ulcer, after retracting the lids properly and after cleaning any discharge or debris from the vicinity of the ulcer.

### **Processing of samples:**

The each scraped corneal tissue sent to the microbiology lab for confirmation of fungus (by KOH wet mount and culture) and to rule out the presence of bacteria (by Gram stain).

### **KOH mount:**

**Principle:** In KOH mount, 10% KOH dissolve the material between the cells, digest the proteinaceous debris and bleach many pigments of the scraped material and thus clearing up the background against which the fungi are clearly seen.

**Procedure:** A drop of 10% KOH placed over a glass slide and mixed with a small quantity of the corneal scrape. A cover slip placed over the drop of KOH. The slide passed over the flame two to three times and examined under the microscope (40X).

**Observation:** A positive report shows the presence of septate and branching hyphae. A negative report shows absence of any fungal elements seen in the KOH mount.

### **Culture and identification:**

Sabouraud's dextrose agar (SDA) slants are used for the identification of mycelia fungi and distinguishing it from yeasts. For primary isolation of fungus, the sample inoculated onto a set of 2 bottles containing Sabouraud's Dextrose agar with and without antimicrobial:

- S.D.A. Plain-'P'
- S.D.A. with Gentamycin and Chloromphenicol (Actidione)- 'G+C' without cycloheximide

All culture's are incubated at 25-35 degree C in the incubator.

For reading of culture: 3 examinations per week for the first two weeks. The culture then examine twice weekly. The culture hold for 21 days (3 weeks) before discarding them as negative.

### **TREATMENT:**

After corneal scraping, topical antibiotics such as Moxifloxacin 0.5%, Tobramycin 0.3% each 2 hrly, a cycloplegic as Atropine 1% TDS, and intra ocular pressure lowering agent as Timolol 0.5% BD in each group of patients are started.

In Voriconazole group patients, 1 % topical Voriconazole is started 2 hourly and in Natamycin group patients, 5% topical Natamycin is started 2 hourly. These patients are enrolled in study only after confirmation of fungal corneal ulcer after microbiology report.

All the cases were followed up weekly for first month and then every two weekly for next two

months. The response to therapy was judged by the following criteria:

- Complete healing time: defined as the period from start of treatment to the flourecien negative stage
- Pretreatment and post treatment vision

## **MediEdunet**

### **You tube Channel**

*Series of Physiology lectures for medical students*

*Subscribe & share ....*

**Medworld asia**

## **Applied Physiology & Anatomy Digest**

Now indexed in **Google scholar & Index Copernicus**

**Dedicated print speciality Journal for Anatomy & Physiology**

---

**www.apad.co.in**

**RESULTS**

**Table No. 1**

**Distribution according to average complete healing time (weeks) of group V and group N subjects**

Complete healing time (weeks)	Group V		Group N	
	No.	%	No.	%
<5	22	78.57%	15	55.55
>5	6	21.42%	12	44.45
Total	28	100.00	27	100.00

$\chi^2 = 3.30$

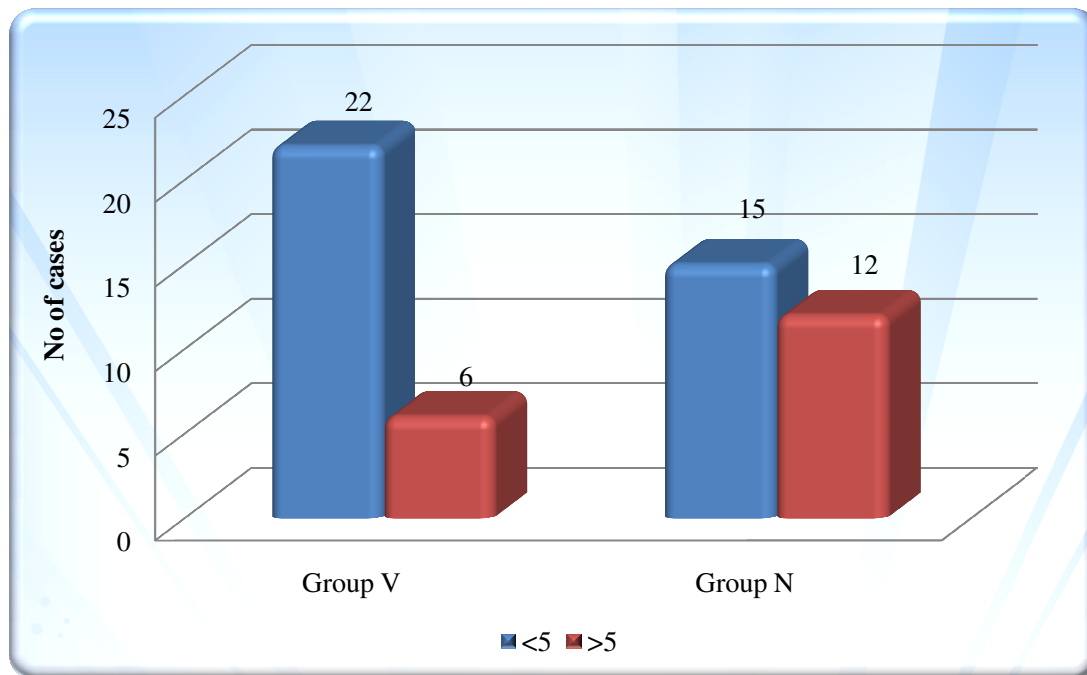
d.f. =1

P value =0.068

NS

This table shows that the complete healing of corneal ulcer within 5 weeks occurs in more patients in the group 'V' than the group 'N' and complete healing takes more than 5 weeks in more patients in the group 'N' than the 'V' group i.e complete healing occurs earlier in group 'V' than the group 'N' that is statistically not significant.

**GRAPH 1**



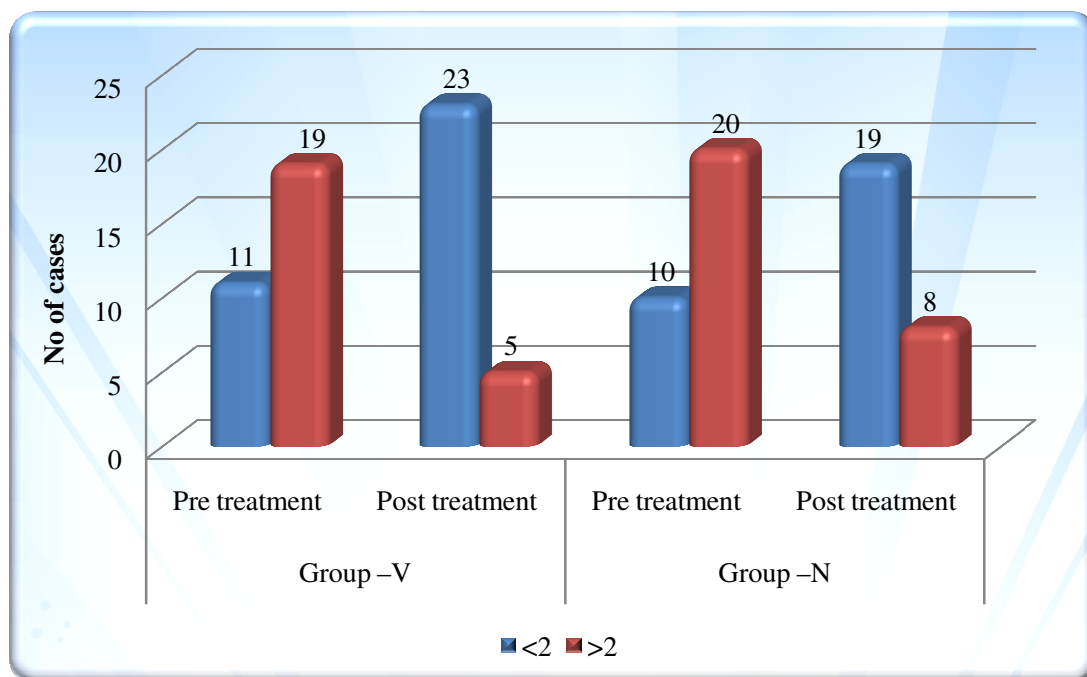
**Table No. 2**

**Distribution according to logMAR Vn of Group-V and Group-N subjects**

logMAR Vn	Group -V		Group -N	
	Pre treatment	Post treatment	Pre treatment	Post treatment
<2	11	23	10	19
>2	19	5	20	8
Total	30 (%)	28 (%)	30 (%)	27 (%)
P value	0.000 (S)		0.000 (S)	

This table shows the improvement in the logMAR vision after treatment in both groups, that was statistically significant in both groups, but improvement was better in the group ‘V’ than the group ‘N’.

**GRAPH 2**



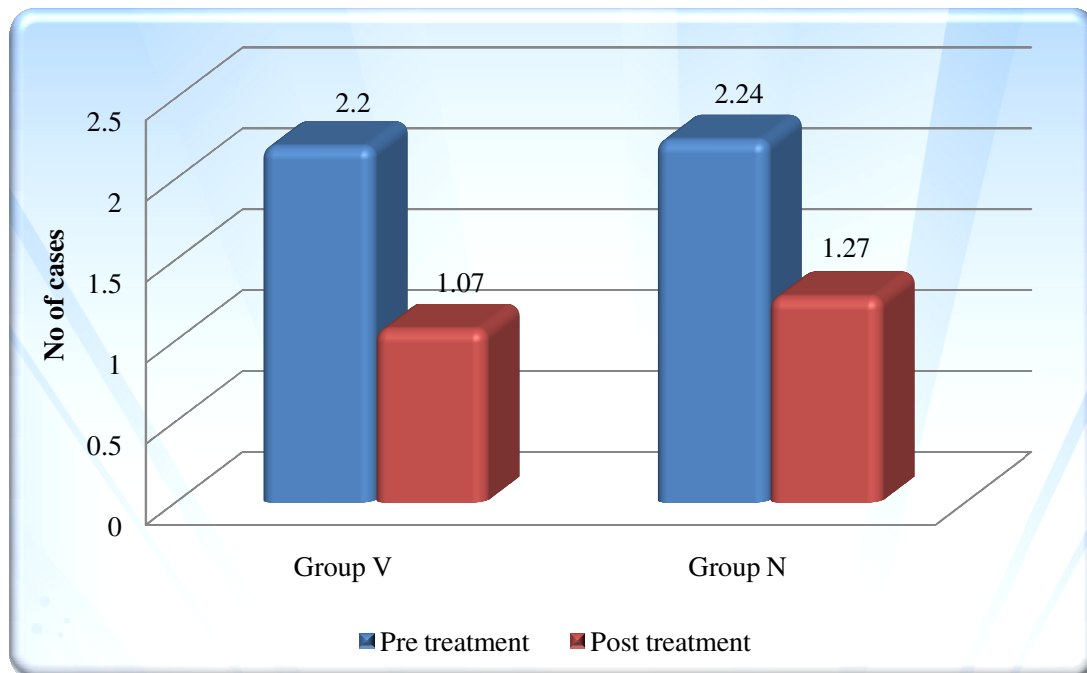
**Table No. 3**

**Mean ± SD of to log MAR Vn of group V and Group N subjects**

Groups	logMARVn		Mean change±SD	P value	Significance
	Pre treatment	Post treatment			
Group V	2.208±1.062	1.071±0.50	1.21±0.89	0.000	S
Group N	2.24±0.917	1.30±0.480	1.07±0.907	0.000	S

This table shows the mean and SD of the logMAR vision improvement in both groups and shows that improvement in the group ‘V’ was 54.80% and in the group ‘N’ improvement was 47.76% i.e improvement was greater in ‘V’ group in comparison to the group ‘N’ after treatment, that was highly significant (HS) in both groups.

**GRAPH 3**



**DISCUSSION**

Infectious keratitis is an important cause of monocular blindness worldwide, in some places upto 50% keratitis are due to fungal infection. Treatment of fungal keratitis is difficult and final outcome in respect of visual acuity is not so good. Fungal keratitis has been common in warmer climate as in India, and relatively uncommon in temperate regions. Fungal keratitis may be caused by ocular trauma with

organic matter or may be related to contact lens wear or refractive surgery. If it is not treated successfully, fungal keratitis may lead to fungal endophthalmitis or ocular perforation.

Early and specific diagnosis of fungal corneal ulcer is necessary for starting of antifungal therapy and to avoid the complications that can arise



from misdiagnosis and delayed treatment. Treatment usually goes for months due to slow healing process.

In this study time taken in complete healing of corneal ulcer showed difference in the two groups. In 'V' group patients complete healing occurred within 5 weeks in 78.57% of patients while in group 'N' only 55.55% corneal ulcers healed completely in 5 weeks. Earlier healing of corneal ulcer in the Voriconazole ('V') group is statistically not significant (p value 0.05).

In this study visual outcome in patients with Pre treatment LogMAR vision more than or equal to 2 (PL+,PR accurate, HM 2 ft, FC 2ft and 3/60 or less on Snellen's chart) and In patients with pre treatment logMAR vision less than 2 (that can be taken on the Snellen's chart as the 4/60 and above) was statistically significant (p-value 0.05) in both groups but better improvement was seen in the group 'V' patients.

To conclude, in our study topical Natamycin and Voriconazole was found to be effective and safe

in the treatment of fungal corneal ulcer. Voriconazole 1 % was more effective than Natamycin 5% in the treatment of fungal corneal ulcer. The use of topical Voriconazole for the treatment of fungal corneal ulcer should be encouraged in an attempt to increase the healing of corneal ulcer and to improve the final visual outcome. Being expensive cost factor of Voriconazole should be considered in individual case.

### CONCLUSIONS

Hence, it can be stated that Voriconazole is comparable to Natamycin in coverage of fungal spectrum but may be more useful in controlling the fungal corneal infection with deeper infiltration of the corneal layers and into the anterior chamber. Voriconazole may decrease the chances of complications of deeper fungal corneal infections such as perforation and endophthalmitis and helps in faster control of fungal keratitis.

### BIBLIOGRAPHY :

- 1) WHO Publications SEA-Ophthal- 126
- 2) Myron YONOFF & Jay S. DUKER Ophthalmology, 3rd edition, 4.13;262.
- 3) Parsons diseases of the eye,21st edition; 189-190
- 4) Whitcher JP, Srinivasan M, Upadhyay MP. Corneal blindness: a global perspective. Bull World Health Organ. 2001;79(3):214-22 1.
- 5) Srinivasan M, Gonzales CA, George C, et al. Epidemiology and aetiological diagnosis of corneal ulceration in Madurai, South India. Br J Ophthalmol. 1997;81(11):965-971.
- 6) Sharma S, Srinivasan M, George C. The current status of Fusarium species in mycotic keratitis in South India. Indian J Med Microbiol 1993; 11: 140-7.
- 7) Venugopal PL, Venugopal TL, Gomathi A, et al: Mycotic keratitis in Madras. Indian J Pathol Microbiol 32:190, 1989
- 8) Sundaram BM, Badrinath S, Subramanian S: Studies on mycotic keratitis. Mycoses 32:568, 1989.